

Systematic Review of Methods and Prognostic Value of Mitotic Activity – Part

2: Canine Tumors

Christof A. Bertram ¹, Taryn A. Donovan ², Alexander Bartel ³

¹ University of Veterinary Medicine Vienna, Vienna, Austria

² The Schwarzman Animal Medical Center, New York, USA

³ Freie Universität Berlin, Berlin, Germany

Corresponding author:

Alexander Bartel, Department of Veterinary Medicine, Institute for Veterinary
Epidemiology and Biostatistics, Freie Universität Berlin, Koenigsweg 67, Berlin,
14163 Berlin, Germany. Email: Alexander.Bartel@fu-berlin.de

Abstract

One of the most relevant prognostication tests for tumors is cellular proliferation, which is most commonly measured by the mitotic activity in routine tumor sections. The goal of this systematic review is to scholarly analyze the methods and prognostic relevance of histologically measuring mitotic activity in canine tumors. A total of 137 articles that correlated the mitotic activity in canine tumors with patient outcome were identified through a systematic (PubMed and Scopus) and manual (Google Scholar) literature search and eligibility screening process. These studies determined the mitotic count (MC, number of mitotic figures per tumor area) in 126 instances, presumably the mitotic count (method not specified) in 6 instances and the mitotic index (MI, proportion of mitotic figures per tumor cells) in 5 instances. A particularly high risk of bias was identified in the available details of the MC methods and statistical analysis, which often didn't quantify the prognostic discriminative ability of the MC and only reported p-values. A significant association of the MC with survival was found in 72/109 (66%) studies. However, survival was evaluated by at least three studies in only 7 tumor types/groups, of which a prognostic relevance is apparent for mast cell tumors of the skin, cutaneous melanoma and soft tissue sarcoma of the skin. None of the studies on the MI found a prognostic relevance. Further studies on the MC and MI with standardized methods are needed to prove the prognostic benefit of this test for further tumor types.

Keywords

Dog, Mitosis, Mitotic Count, Mitotic figure, Mitotic Index, Neoplasia, Outcome, Survival

Introduction

Dogs with malignant tumors exhibit a variable clinical course based on certain tumor and patient characteristics.⁹¹ One of the most relevant tumor characteristics regarding prognostication is cellular proliferation.^{42,91} While most measurement methods of tumor proliferation require immunohistochemistry (such as the Ki67 index) or special stains (such as the AgNOR score), the most practical approach is to measure mitotic activity in routine Hematoxylin and Eosin-stained tumor sections.¹³⁸

The histological measurement methods for mitotic activity (quantification of mitotic figures, i.e. cells in the M-phase of cell division with histologically distinct features) varies largely in previous studies.⁹¹ Two broad categories can be distinguished: 1) The mitotic count (MC) represents the absolute number of mitotic figures per tumor area and 2) the mitotic index (MI) represents the proportion of mitotic figures among all tumor cells per tumor area.⁹² While there are recent efforts, starting in 2016, to standardize the measurement method of the MC,^{42,91,92} many studies were published before those guidelines. An overview of the previously applied methods is needed to better understand current practice and to direct future recommendations.

A vast number of studies have evaluated mitotic activity (mostly the MC) as a prognostic test in several canine tumor types (see result section). While mitotic activity is generally considered to be associated with the biological behavior of tumors and outcome of tumor patients,^{42,91} there are currently no tumor type-specific recommendations for the routine assessment of mitotic activity. Due to the methodological differences in prognostic studies and the intrinsic bias of observational studies, validation of research findings and summaries through systematic review (and ideally meta-analysis) are needed for each tumor type.^{17,90}

The goal of this systematic review is to scholarly analyze the methods and prognostic relevance of histologic measuring mitotic activity in canine tumors. We intend to give an overview of current literature and derive recommendations for routine diagnostic practice and future research goals.

Material and Methods

This systematic review was conducted in the similar way as a previous systematic review on mitotic activity in feline tumors using the same literature search protocol (with modified search terms and a single literature reviewer), data extraction and article evaluation (risk of bias) criteria.¹⁴

Literature search

References were identified through systematic (predefined search terms) and manual (free search terms) search to ensure literature saturation (Fig. 1). Eligibility screening was carried out by a single author (CAB) using a two-step procedure.

Systematic literature identification was carried out in two databases, namely PubMed (1950 to present) and Scopus (1970 to present), on April 30th 2022 using following predefined search terms: (Dog OR dogs OR canine) AND (mitotic count OR mitotic index). Duplicates were removed, and the two-step eligibility screening was carried out in Rayyan¹⁰⁶ using the inclusion/exclusion criteria as provided in Table 1.

Manual literature search in Google Scholar and the perusal of cited references (“cited by” search in google scholar) was conducted in 2022 until 30th April 2022. During literature search, the aforementioned eligibility criteria were applied and only articles that meet these criteria were included. Duplicates to the systematic literature search were excluded.

Table 1. Summary of the inclusion/exclusion criteria for the two eligibility screening steps applied to the identified references.

Screening Step	Decision category	Inclusion criteria	Exclusion criteria	
Title-abstract	1) Study design	Original study, peer-reviewed	Case-reports, reviews	
	2) Topic	a) Species	Dog / Canine	Other species
		b) Tumor	Spontaneous tumors	Experimentally induced tumors
			Malignant tumors with potential for metastasis	Benign tumors
		c) Prognostic test	Mitotic count (MC), mitotic index (MI)	No mitotic activity measurement
	d) Examination method	Histology	Cytology	
3) Language of main text		English or German	Other language	
Full text	1) Article accessibility	Article accessible	Article inaccessible	
	2) Topic	a) Patient outcome	Correlation of the MC/MI with survival, tumor progression, metastasis, or recurrence	No correlation of the MC/MI with patient follow-up

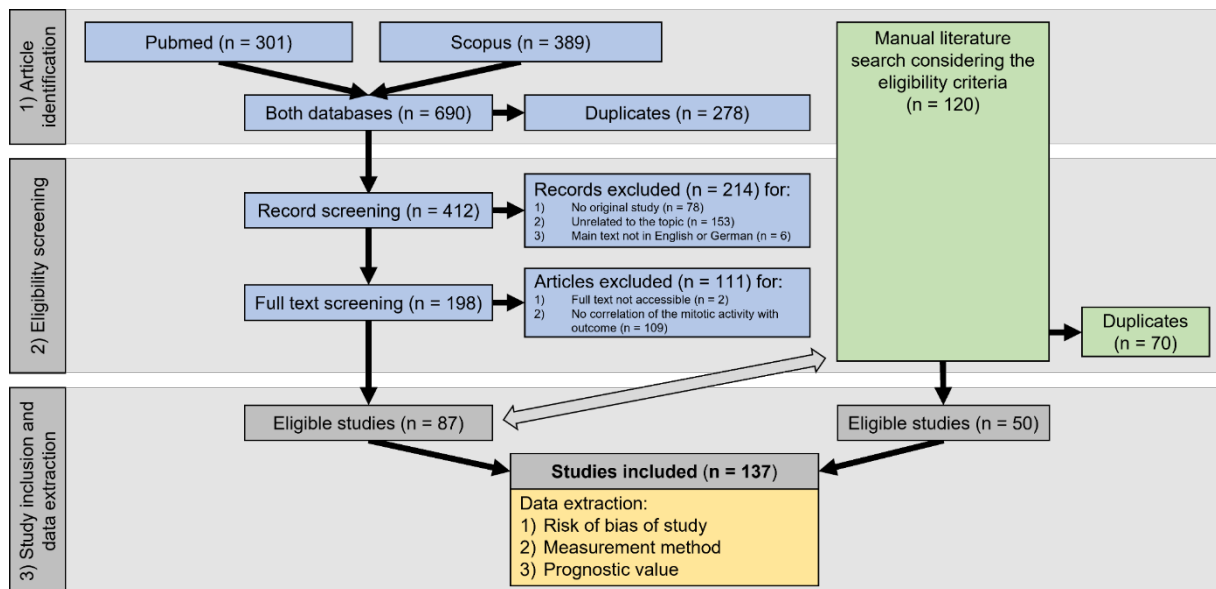


Figure 1. Flow diagram (based on the PRISMA recommendation) of the literature search divided into systematic (blue boxes) and manual (green boxes) article identification and eligibility screening, followed by study inclusion with subsequent data extraction.

Data extraction and analysis

Information regarding the publication (paper identification, year of publication, journal), tumor type evaluated, measurement methods of the MC or MI, prognostic value of mitotic activity was extracted from each article in the same way as previously described.¹⁴ Risk of bias of each study was evaluated (low, moderate, high) specifically for the information regarding the mitotic activity using a precisely developed protocol¹⁴ for more objectivity. The overall risk of bias was based on four domains: 1) study population, 2) outcome assessment, 3) Mitotic activity methods, 4) data analysis.

Results

Study selection

The article identification and eligibility screening process are summarized in Fig. 1. Through the systematic literature search, 87 eligible articles out of 412 unique references were identified. Fifty additional articles were found during manual literature search, summing up to a total of 137 articles evaluated in this systematic review.^{1-3,5,7-}

11,16,18-20,22-28,30-36,38-41,43-48,50-63,66-72,75-81,83-89,93-105,107-119,121-137,139-147,149-161

Study characterization

All of the included articles were written in English. One third (42/137, 31%) of the publications were published in journals focused on veterinary pathology (Vet Pathol, J Comp Pathol and J Vet Diagn Invest).

Based on the described method, 126 articles evaluated the MC (number of mitotic figures per tumor area),^{2,3,5,7-11,16,18-20,22-28,30-36,38-41,43-48,50-63,66,67,69-72,75-81,83-89,93,96-105,110-119,121-123,125-128,130-133,135-137,139-147,149-158,160,161}, 5 evaluated the MI (proportion of mitotic figures per number of tumor cells)^{95,109,124,134,159} and 6 did not specify the mitotic activity method in their paper.^{1,68,94,107,108,129} We assume that the articles without method specification performed the MC, summing up to a total of 132 articles (96.4%). The number of articles included in this review published per year increased over time with more than 10 articles per year between 2018-2021 (Fig. 2).

Whereas the 5 references that determined the MI always used the preferred term “mitotic index”, the other 132 articles on the MC use various and sometimes multiple terms including mitotic index (N = 83), mitotic count (N = 40), mitotic rate (N = 13), number of mitosis (N = 3), number of mitotic figures (N = 1), number of mitotic cells (N

= 1), mitotic figures (N = 1), and mitosis (N = 1). Since publishing recommendations on the terminology in 2016⁹², the frequency of the use of correct terminology for MC has improved. While only 12/82 (15%) of the articles published before 2017 used the correct term, 28/55 (51%) after 2016 used the recommended terminology (Fig. 2). Usage of the correct term after 2016 was even higher when the journal had a veterinary pathology focus (12/14, 86%) compared to other journals (16/41, 39%).

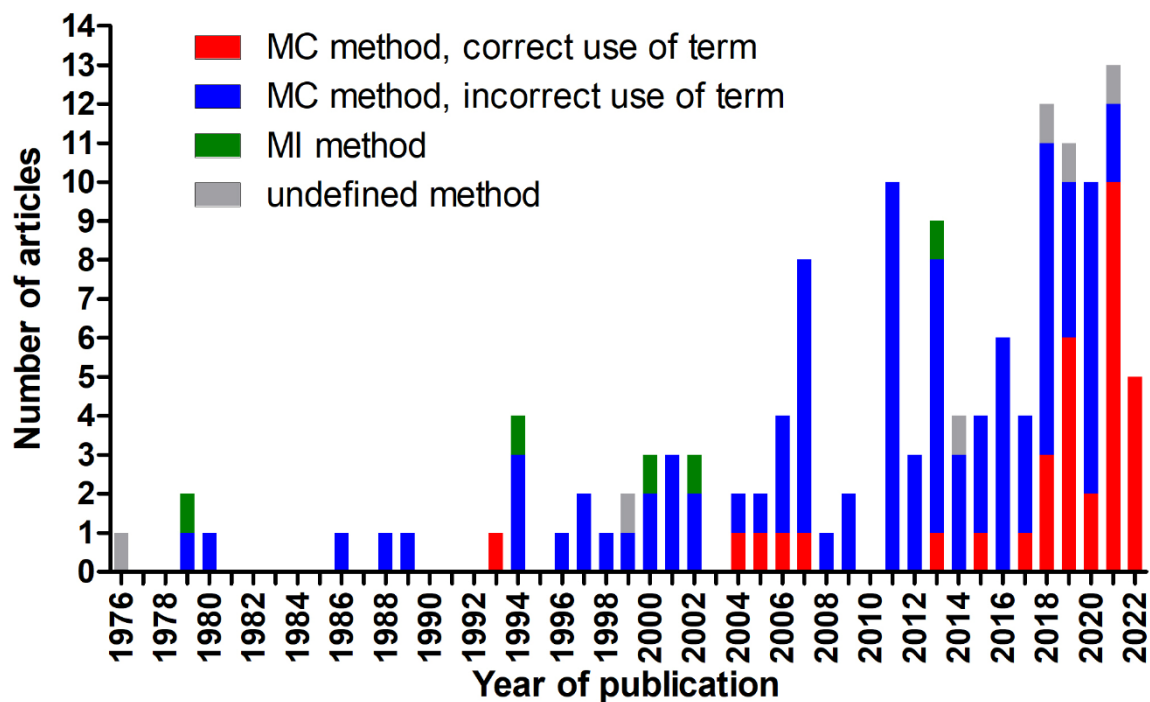


Figure 2. Stacked bar chart of the number of publications included in this systematic review per year of publication. The year 2022 includes publications until April 30th.

MC, mitotic count; MI, mitotic index

Descriptive summary

Mitotic count (MC)

The 132 studies on the MC evaluated numerous tumor types, whereas some studies included several tumor types or tumor locations or lacked relevant information on these tumor specifications (Table 2).

Table 2. Number of articles per tumor type/group and tumor specifications based on tumor types or locations.

Tumor type/group	Number of references	Tumor specifications of the articles
Mast cell tumors	29 (22%)	Skin (N = 24), cutaneous and subcutaneous), skin and mucocutaneous (N = 2), intramuscular (N = 1), oral mucosa (N = 1), unspecified location (N = 1)
Soft tissue tumors	21 (16%)	Skin (N = 13), gastrointestinal (N = 4), visceral (N = 1), smooth muscle tumor (N = 1), appendicular, axial skeleton soft tissue and visceral (N = 1), unspecified location (N = 1)
Melanocytic tumors	20 (15%)	Oral (N = 9), cutaneous (N = 4), oral and cutaneous (N = 5), (intra)ocular (N = 2)
Mammary tumors	14 (11%)	Malignant tumors (N = 8), any (N = 4), carcinoma (N = 1), neuroendocrine carcinoma (N = 1)
Osteosarcoma	9 (7%)	Appendicular (N = 5), mandibular (N = 1), surface (N = 1), any (N = 2)
Lymphoma	8 (6%)	Multicentric (N = 2), diffuse large B-cell (N = 1), diffuse small B-cell (N = 1), Burkitt-like (N = 1), indolent (N = 1), small intestinal (N = 1), any (1)
Hemangiosarcoma	7 (5%)	Splenic (N = 2), cutaneous (N = 1), subcutaneous and intramuscular (N = 1), other than skin (N = 1), non-visceral (N = 1), falciform fat (N = 1)
Apocrine gland anal sac adenocarcinoma	5 (4%)	–
Splenic tumors	4 (3%)	Mesenchymal/stromal sarcoma (N = 2), fibrohistocytic nodules (N = 2)
Pulmonary tumors	3 (2%)	–
Renal cell carcinoma	2	–
Insulinoma	2	–
Squamous cell carcinoma	2	Skin (N = 2)
Salivary gland tumors	1	–
Glial tumors	1	–
Synovial sarcoma	1	–
Thymic tumors	1	–
Pheochromocytoma	1	–
Esophageal sarcoma	1	–

Risk of bias

The risk of bias of each of the four domains and the overall risk of bias is summarized in Table 3. Most studies (70/132, 53%) had a high overall risk of bias based on a high risk in at least one of the four domains. One study included some feline cases in the study population,¹²⁸ which poses a high risk of bias as equality in the extent of the association of the MC with outcome between different species should not be expected. Data analysis (domain 4) was often restricted to a statistical test of significance and in many studies with non-significant results the actual p-values were not even reported.

Table 3. Summary of the risk of bias evaluation for all studies on the mitotic count combined. The overall risk of bias was based on four domains (D1-D4).

Risk of bias	Number and percent of articles				
	D1: Study population	D2: Outcome assessment	D3: MC methods	D4: Data analysis	Overall
Low ⊕	28 (21%)	17 (13%)	19 (14%)	6 (5%)	4 (3%)
Moderate ○	68 (52%)	92 (70%)	20 (15%)	61 (46%)	58 (44%)
High ⊖	36 (27%)	23 (17%)	93 (70%)	65 (49%)	70 (53%)

Methods

The MC values were taken from pathology records in 19/132 studies (14%), partially taken from pathology reports and newly determined in 2/132 studies (2%) and likely newly determined for the study following the study protocol in the remaining 111 studies (84%). One study employed a semi-quantitative scoring to assessing mitotic density⁸⁹, while the rest enumerated mitotic figures. Special staining methods were used in one study (Toluidine blue).¹¹² Seven of the 20 studies (35%) on melanoma

specified that they used bleached slides (for all cases or for heavily pigmented cases), and two studies (10%) assigned a mitotic count of 0 when nuclei were obscured by pigmentation. One study evaluated the MC in digital whole slide images (20x and 40x scan magnification) and glass slides,¹⁵⁴ while the remaining studies (presumably) used light microscopy. The use of automated image analysis was not reported in any study.

A summary of the key methodical aspects of the mitotic count applied in the 132 studies is depicted in Fig. 3. Generally, the proportion of studies that reported the details on the MC methods increased for studies published after 2017 and in journals with a focus on pathology.

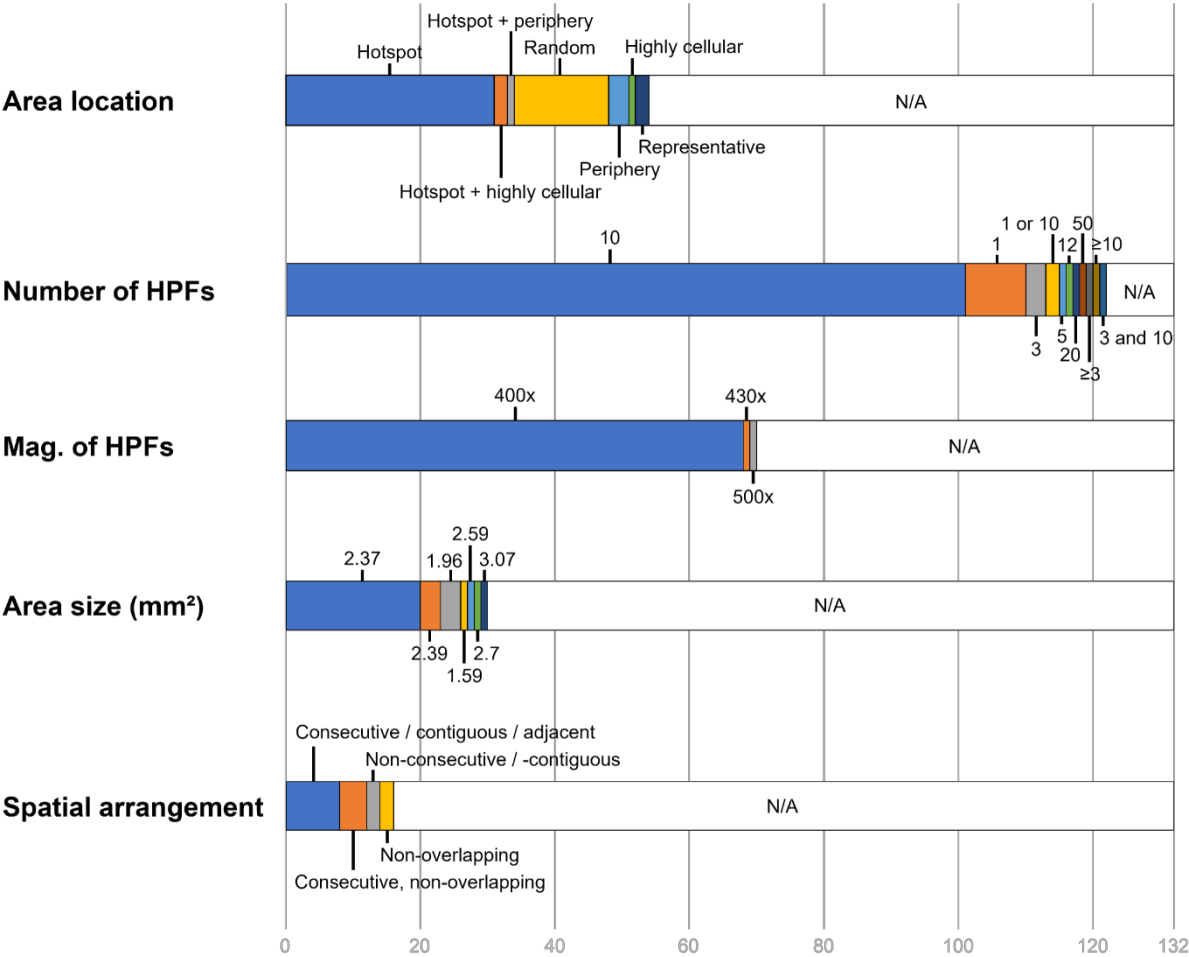


Figure 3. Stacked bar chart for the key methodical aspects of the mitotic count applied in the 132 studies.

HPFs, high-power fields; Mag., magnification; N/A, not available

Prognostic value

The outcome metrics evaluated in the 132 studies were survival (N = 113, 86%), disease progression (occurrence of metastasis or local recurrence; N = 40, 30%), metastasis (N = 26, 20%), recurrence (N = 22, 17%, particularly for soft tissue tumors), and recurrence of hypoglycemia in insulinoma (N = 2, 2%). The number of complete cases varied between 6 and 384 (median: 50 cases; mean: 64 cases). The prognostic relevance of the MC for different pathologists was only determined in one study.¹²⁶

For all tumor types/groups combined, a prognostic value (mostly determined using statistical significance) was found in 55% to 63% of the studies regarding the different outcome metrics as summarized in Table 4. The association of the MC with survival for the tumor types/groups with 3 or more studies are summarized in Fig. 4. However, the discriminant ability of the prognostic test can not be properly evaluated for many studies due to the lack of appropriate statistical analysis.

Survival was evaluated in 23 studies on mast cell tumors of skin (cutaneous and subcutaneous). A shorter survival was found for cases with higher MCs in 21/23 (91%) studies, while 2/23 (9%) studies did not reach statistical significance. A relevant discriminant ability of the MC is suggested by the AUC values of 0.78, 0.79 and 0.82. The sensitivity and specificity values for the different proposed cut-off stratifications, reported in 9 individual studies, are illustrated in Fig. 5. Higher MCs were significantly associated with shorter disease-free intervals in 8/10 (80%) studies and with occurrence of metastasis or recurrence in each 4/6 studies (67%).

For cutaneous and oral melanoma, higher MC values indicated shorter survival 11/17 (65%) studies. Interestingly, analysis of only cutaneous melanoma found a prognostic

significance in 4/5 studies (80%), analysis of only oral melanoma in 4/9 studies (44%) and combined analysis of both locations in 4/4 studies (100%). For cutaneous and oral melanoma, a good discriminant ability of the MC is inferred, based on the provided AUC values of 0.78, 0.79 and 0.86. Shorter disease progression was significantly associated with higher MCs in 3/5 studies (60%).

Studies on soft tissue sarcoma of the skin reached statistical significance regarding higher MCs and shorter survival in 6/7 studies (86%). The discriminant ability of the MC is not well demonstrated in these studies. Recurrence was associated with higher MCs in 7/10 studies (70%).

Studies on splenic stromal sarcoma and the former broader category “fibrohistiocytic nodules” found a significant prognostic association of higher MCs values with shorter survival in 3/4 (75%) instances. The failure to reach significance in the one study could be due to a small study population of 8 tumors.

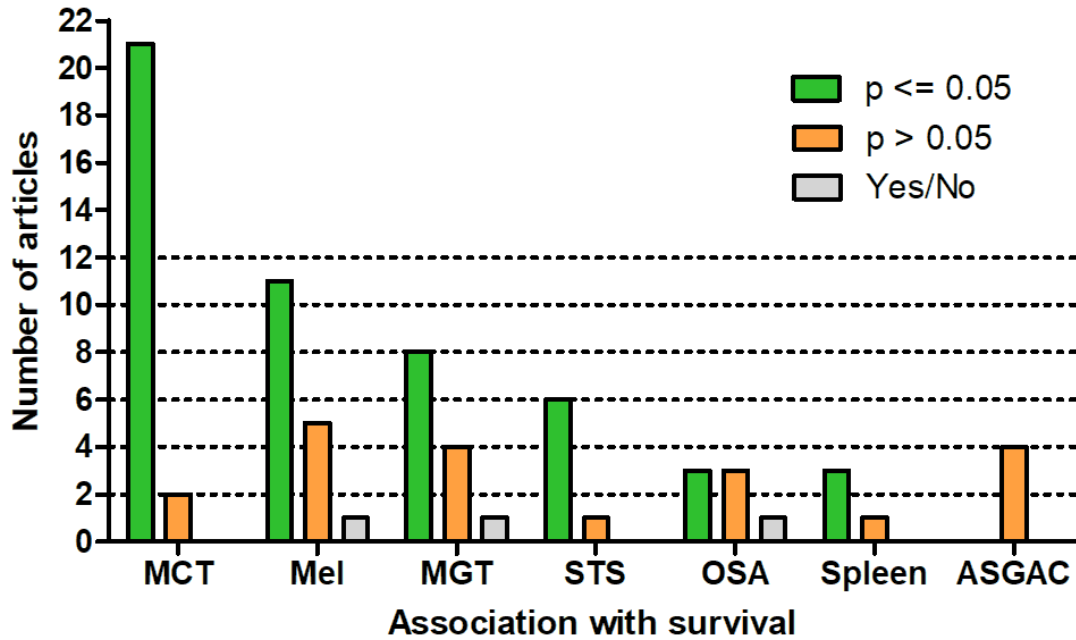


Figure 4. Number of studies that did or did not reach prognostic significance regarding the association of the MC with survival for tumor types with more than three studies. Yes/No describes studies with significant association in only a subset of cases or pathologists.

MCT, mast cell tumor of the skin (cutaneous and subcutaneous); Mel, cutaneous and oral melanoma; MGT, mammary gland tumors; STS, soft tissue sarcoma; OSA, osteosarcoma; Spleen, splenic stromal sarcoma and fibrohistiocytic nodules; ASGAC, anal sac gland adenocarcinoma;

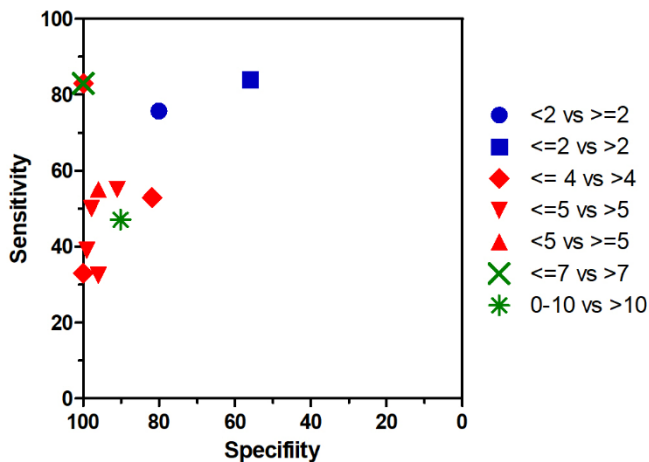


Figure 5. Summary of the sensitivity and specificity for survival in canine mast cell tumors of the skin based on different different cut-off ranges. The data is reported by 9 studies (three with two cut-offs).^{10,11,19,51,55,60,145,151,153}

Table 4. Summary of the prognostic significance (mostly comprising the p-value approach) of all studies on the mitotic count combined regarding survival, disease progression (metastasis or recurrence), metastasis, and recurrence.

Prognostic significance	Number of articles				
	Survival	Disease progression	Metastasis	Tumor recurrence	Recurrence of clinical signs
Yes	69 (63%)	21 (55%)	14 (58%)	11 (55%)	1 (100%)
Yes/No	3 (3%)	0	1 (4%)	0	0
No	37 (34%)	17 (45%)	9 (38%)	9 (45%)	0
ND	4	2	2	2	1
N/A	19	92	106	110	130

Yes/No, prognostic significance was found for only a subset of the cases or pathologists; ND, interpretation of the prognostic significance is not provided (individual patient data available); N/A, outcome metric not available

Mitotic index (MI): Risk of bias, MI methods, and prognostic value

The MI was determined in 5 studies that each evaluated a different tumor type: skeletal osteosarcoma,⁹⁵ multicentric lymphoma,¹⁰⁹ malignant mammary tumors,¹²⁴ mast cell tumors of the skin,¹³⁴ and aortic body tumors¹⁵⁹. The overall risk of bias of these articles was judged to be high (n = 4) or moderate (n = 1) particularly pertaining to the data analysis domain.

The MI determination methods varied among studies. Four studies described the staining method, of which two used HE^{109,159}, one employed toluidine blue¹²⁴, and one utilized anti-PCNA immunolabeled slides.¹³⁴ The proportion of mitotic figures was calculated amongst varying numbers of tumor cells: 500,¹⁰⁹ 1,000 (in PCNA hotspot¹³⁴ or peripheral areas⁹⁵), at least 10,000,¹⁵⁹ and all cells within 10 hotspot HPFs (at 25x magnification).¹²⁴ Two studies created photomicrographs for counting,^{124,159} with one also using software for cell number estimation.¹²⁴

None of the studies did reach statistical significance for the association of the MI with survival time (N = 2) or metastasis (N = 3). Only 1/2 studies determined that higher MIs were significantly associated with tumor recurrence.

Discussion

The prognostic relevance of mitotic activity has been evaluated in many studies on canine tumors enabling this extensive systematic review. Canine studies on this topic were more numerous than feline studies, encompassing more than 3 times greater the numbers of articles,¹⁴ and studies for other animal species are almost nonexistent.⁶ This underscores an apparently greater research interest in canine tumors. Nevertheless, the findings of this systematic review on canine tumors was similar to the findings of a previous systematic review on feline tumors regarding the risk of bias in the studies.¹⁴ For many tumor types the prognostic relevance of mitotic activity is still not convincingly proven considering the study limitations and lack of validation studies, as will be discussed below. Since our literature search for this systematic review, several articles on the MC have been published^{21,29,37,49,64,73,74,82,120,148} and the number of new references is expected to markedly increase with time given the enormous increase of research interest over the last decade. Repetition of this systematic review will be required when new evidenced based literature allows new conclusions to be drawn on the prognostic value of the MC and MI in canine tumors.

MC Methods

The MC represents the routine method of measuring mitotic activity with microscopic tumor evaluation. However, a wide variety of MC methods have been applied in previous studies and often the methods have not been described in sufficient detail.

Each study should describe the key aspects of the MC methods, including: 1) the region of interest selection, 2) area size (in mm²), and 3) spatial arrangement of HPF. While the best method regarding reproducibility and prognostic ability is current unknown, standardization, as previously proposed,⁹¹ may improve comparability between studies and unify the diagnostic workflow between different tumor types. However, future studies are needed to determine which of these methods have the highest prognostic value and reproducibility between pathologists.¹²⁶

Many laboratories have completely switched to digital microscopy¹⁵ and high consistency with light microscopy has been shown by several studies (summarized by Donovan et al.⁴²). Nevertheless, only few prognostic studies on canine tumors have used digital microscopy and correlated the digital counts with outcome.¹⁵⁴ Digital microscopy has some particular requirements such as the differences in size of HPFs that need to be considered for quantification of mitotic activity.^{15,65} However, digital images also introduce new possibilities for standardized assessment of mitotic figures such as counting tools in viewing software and image analysis algorithms.^{12,13} In particular, deep learning-based algorithms are considered promising to improve time efficiency, reproducibility and accuracy for this task (computer-assisted mitotic counts).^{4,12}

Prognostic Value of the MC

Tumor cell proliferation is one key driver of tumorigenesis, and thus the MC is often assumed to correlate with outcome. However, a surprisingly high proportion of studies did not find a prognostic value (using statistical significance) for the MC in canine tumors. It should be noted that interpretation of these results are difficult, since many studies restricted their analysis to tests of significance (p-value approach), which

cannot be used to establish prognostic value (effect size) or lack thereof.¹⁷ We recommend correlating the MC with relevant endpoints by multiple statistical methods including the Kaplan-Meier curves, hazard ratios, sensitivity and specificity. Cut-off agnostic methods like ROC curves and their area under the curves (AUC) are particularly preferred.¹⁷

Of note, conflicting findings between studies were found for most of the evaluated tumor types/groups. This highlights the general high risk of bias of observational studies and the need for several validation studies before sufficient evidence of the prognostic value of the MC can be guaranteed. Possible explanations for the lack of prognostic relevance in these studies include small study populations, heterogeneous tumor groups (different tumor entities or locations), variable MC methods, and, as will be discussed in more detail below, flawed statistical methods.

We have noted that the results for the prognostic relevance of the MC were quite variable between different studies (as demonstrated for mast cell tumors). Besides the aforementioned limitations, the differences in the results can be explained by variability between pathologists in assessing the MC. While a high degree of inconsistency between pathologists has been shown by several studies,^{4,12,13,154} the influence on prognostication is largely unexplored.¹²⁶ For example, it has been determined that some pathologists are rather sensitive when distinguishing mitotic figures from imposters (resulting in higher MCs), while other pathologists are rather specific (resulting in lower MCs).^{4,12} We argue that this variability between pathologists might have an important influence on the prognostically most meaningful cut-off values, possibly resulting in unexpected performance of the prognostic test when applied routinely by various pathologists in a diagnostic setting.

Based on our systematic review, we conclude that the MC has a prognostic value for canine mast cell tumors of the skin, cutaneous melanoma, soft tissue tumors of the skin and splenic stromal sarcoma, thus determination of the MC is recommended for routine diagnostic service for these tumor types. While the discriminant ability seems to be good for mast cell tumors of the skin and cutaneous melanoma, it requires further evaluation for the other tumor types. For anal sac gland adenocarcinoma, the MC truly seems to have little prognostic value based on several studies. The results for the prognostic value of the MC are conflicting for mammary tumors, oral melanoma and osteosarcoma and unproven for all the other tumor types considering the lack of validation studies.

MI

In contrast to the MC, the MI has been rarely evaluated in the current literature, most likely explained by the inability to apply to routine diagnostic service. Improved time efficiency of the MI and thus applicability for routine diagnostics may be achieved in the future by the use of automated image analysis for tumor cells enumeration. It seems logical that the mitotic activity measurement is more representative for the case when set in relation to the cellular density, particularly in tumor types (such as mammary carcinoma) that exhibit variable cellular density due to extensive extracellular matrix, cystic spaces, inflammation or edema. Surprisingly, the few studies on canine tumors did not find a significant association with survival or metastasis, in contrast to the studies on feline mammary tumors.¹⁴ However, the canine studies did not compare the MI to the MC and validation studies for each tumor type are not available.

Conclusions

Mitotic activity is a relevant prognostic test that was evaluated in many studies on canine tumors. While the MI is rarely determined and its prognostic value is largely unexplored, the discriminant ability of the MC with regard to patient outcome has been well demonstrated in some canine tumors (particularly mast cell tumors of the skin, cutaneous melanoma and soft tissue tumors of the skin). Limitations of current studies include small case numbers, combined evaluation of heterogeneous tumor groups, unavailable detail of the MC methods, statistical analysis restricted to the p-value approach, and prognostic cut-offs based on single pathologists. Repetition of this systematic review is needed in several years to update conclusions and recommendations.

Acknowledgements

None

Declaration of conflict of interest

None

Funding

None

Authors' Contributions

CAB, TAD and AB designed the experiment; CAB performed the systematic review; CAB performed data extraction from the articles; the manuscript was written by CAB with contributions by all authors.

References

1. Able H, Wolf-Ringwall A, Rendahl A, et al. Computed tomography radiomic features hold prognostic utility for canine lung tumors: An analytical study. *PLoS one*. 2021;16: e0256139. doi: 10.1371/journal.pone.0256139
2. Amsellem PM, Selmic LE, Wypij JM, et al. Appendicular osteosarcoma in small-breed dogs: 51 cases (1986-2011). *J Am Vet Med Assoc*. 2014;245: 203-210. doi: 10.2460/javma.245.2.203
3. Aresu L, Agnoli C, Nicoletti A, et al. Phenotypical Characterization and Clinical Outcome of Canine Burkitt-Like Lymphoma. *Front Vet Sci*. 2021;8: 647009. doi: 10.3389/fvets.2021.647009
4. Aubreville M, Stathonikos N, Bertram CA, et al. Mitosis domain generalization in histopathology images - The MIDOG challenge. *Med Image Anal*. 2023;84: 102699. doi: 10.1016/j.media.2022.102699
5. Avallone G, Pellegrino V, Muscatello LV, et al. Canine smooth muscle tumors: A clinicopathological study. *Vet Pathol*. 2022;59: 244-255. doi: 10.1177/03009858211066862
6. Bacci B, Stent AW, Walmsley EA. Equine Intestinal Lymphoma: Clinical-Pathological Features, Immunophenotype, and Survival. *Vet Pathol*. 2020;57: 369-376. doi: 10.1177/0300985820906889
7. Baja AJ, Kelsey KL, Rusler DM, Gieger TL, Nolan MW. A retrospective study of 101 dogs with oral melanoma treated with a weekly or biweekly 6 Gy × 6 radiotherapy protocol. *Vet Comp Oncol*. 2022. doi: 10.1111/vco.12815
8. Berger EP, Johannes CM, Jergens AE, et al. Retrospective evaluation of toceranib phosphate (Palladia®) use in the treatment of gastrointestinal stromal tumors of dogs. *J Vet Intern Med*. 2018;32: 2045-2053. doi: 10.1111/jvim.15335
9. Bergin IL, Smedley RC, Esplin DG, Spangler WL, Kiupel M. Prognostic evaluation of Ki67 threshold value in canine oral melanoma. *Vet Pathol*. 2011;48: 41-53. doi: 10.1177/0300985810388947
10. Berlato D, Murphy S, Laberke S, Rasotto R. Comparison of minichromosome maintenance protein 7, Ki67 and mitotic index in the prognosis of intermediate Patnaik grade cutaneous mast cell tumours in dogs. *Vet Comp Oncol*. 2018;16: 535-543. doi: 10.1111/vco.12412
11. Berlato D, Murphy S, Monti P, et al. Comparison of mitotic index and Ki67 index in the prognostication of canine cutaneous mast cell tumours. *Vet Comp Oncol*. 2015;13: 143-150. doi: 10.1111/vco.12029
12. Bertram CA, Aubreville M, Donovan TA, et al. Computer-assisted mitotic count using a deep learning-based algorithm improves interobserver reproducibility and accuracy. *Vet Pathol*. 2022;59: 211-226. doi: 10.1177/03009858211067478
13. Bertram CA, Aubreville M, Gurtner C, et al. Computerized Calculation of Mitotic Count Distribution in Canine Cutaneous Mast Cell Tumor Sections: Mitotic Count Is Area Dependent. *Vet Pathol*. 2020;57: 214-226. doi: 10.1177/0300985819890686
14. Bertram CA, Donovan TA, Bartel A. Systematic Review of Methods and Prognostic Value of Mitotic Activity. Part 1: Feline Tumors. *arXiv preprint arXiv:230501403*. 2023.
15. Bertram CA, Stathonikos N, Donovan TA, et al. Validation of digital microscopy: Review of validation methods and sources of bias. *Vet Pathol*. 2022;59: 26-38. doi: 10.1177/03009858211040476
16. Boos GS, Bassuino DM, Wurster F, et al. Retrospective canine skin peripheral nerve sheath tumors data with emphasis on histologic, immunohistochemical and prognostic factors. *Pesquisa Veterinaria Brasileira*. 2015;35: 965-974. doi: 10.1590/S0100-736X2015001200005

17. Boracchi P, Roccabianca P, Avallone G, Marano G. Kaplan-Meier Curves, Cox Model, and P-Values Are Not Enough for the Prognostic Evaluation of Tumor Markers: Statistical Suggestions for a More Comprehensive Approach. *Vet Pathol.* 2021;58: 795-808. doi: 10.1177/03009858211014174
18. Bostock DE. Prognosis after surgical excision of canine melanomas. *Vet Pathol.* 1979;16: 32-40.
19. Bostock DE, Crocker J, Harris K, Smith P. Nucleolar organiser regions as indicators of post-surgical prognosis in canine spontaneous mast cell tumours. *Br J Cancer.* 1989;59: 915-918. doi: 10.1038/bjc.1989.193
20. Bostock DE, Dye MT. Prognosis after surgical excision of canine fibrous connective tissue sarcomas. *Vet Pathol.* 1980;17: 581-588. doi: 10.1177/030098588001700507
21. Bray JP, Munday JS. Development of a Nomogram to Predict the Outcome for Patients with Soft Tissue Sarcoma. *Vet Sci.* 2023;10. doi: 10.3390/vetsci10040266
22. Bray JP, Polton GA, McSparran KD, Bridges J, Whitbread TM. Canine soft tissue sarcoma managed in first opinion practice: outcome in 350 cases. *Vet Surg.* 2014;43: 774-782. doi: 10.1111/j.1532-950X.2014.12185.x
23. Camerino M, Giacobino D, Manassero L, et al. Prognostic impact of bone invasion in canine oral malignant melanoma treated by surgery and anti-CD34 vaccination: A retrospective study on 68 cases (2010-2020). *Vet Comp Oncol.* 2022;20: 189-197. doi: 10.1111/vco.12761
24. Canadas A, França M, Pereira C, et al. Canine Mammary Tumors: Comparison of Classification and Grading Methods in a Survival Study. *Vet Pathol.* 2019;56: 208-219. doi: 10.1177/0300985818806968
25. Carvalho MI, Pires I, Prada J, Lobo L, Queiroga FL. Ki-67 and PCNA Expression in Canine Mammary Tumors and Adjacent Nonneoplastic Mammary Glands: Prognostic Impact by a Multivariate Survival Analysis. *Vet Pathol.* 2016;53: 1138-1146. doi: 10.1177/0300985816646429
26. Carvalho MI, Pires I, Prada J, et al. Assessing the interleukin 35 immunoexpression in malignant canine mammary tumors: Association with clinicopathological parameters and prognosis. *Anticancer Research.* 2019;39: 2077-2083. doi: 10.21873/anticancer.13319
27. Carvalho S, Stoll AL, Priestnall SL, et al. Retrospective evaluation of COX-2 expression, histological and clinical factors as prognostic indicators in dogs with renal cell carcinomas undergoing nephrectomy. *Vet Comp Oncol.* 2017;15: 1280-1294. doi: 10.1111/vco.12264
28. Chen YC, Chen YY, Liao JW, Chang SC. Expression and prognostic value of c-met in canine mammary tumours. *Vet Comp Oncol.* 2018;16: 670-676. doi: 10.1111/vco.12439
29. Cherzan NL, Fryer K, Burke B, Farrelly J. Factors affecting prognosis in canine subcutaneous mast cell tumors: 45 cases. *Vet Surg.* 2023;52: 531-537. doi: 10.1111/vsu.13944
30. Chiti LE, Ferrari R, Boracchi P, et al. Prognostic impact of clinical, haematological, and histopathological variables in 102 canine cutaneous perivascular wall tumours. *Vet Comp Oncol.* 2021;19: 275-283. doi: 10.1111/vco.12673
31. Chiti LE, Ferrari R, Roccabianca P, et al. Surgical Margins in Canine Cutaneous Soft-Tissue Sarcomas: A Dichotomous Classification System Does Not Accurately Predict the Risk of Local Recurrence. *Animals (Basel).* 2021;11. doi: 10.3390/ani11082367
32. Cleland NT, Morton J, Delisser PJ. Outcome after surgical management of canine insulinoma in 49 cases. *Vet Comp Oncol.* 2021;19: 428-441. doi: 10.1111/vco.12628

33. Cook MR, Lorbach J, Husb, et al. A retrospective analysis of 11 dogs with surface osteosarcoma. *Vet Comp Oncol.* 2022;20: 82-90. doi: 10.1111/vco.12741
34. Coyle VJ, Rassnick KM, Borst LB, et al. Biological behaviour of canine mandibular osteosarcoma. A retrospective study of 50 cases (1999-2007). *Vet Comp Oncol.* 2015;13: 89-97. doi: 10.1111/vco.12020
35. Crownshaw AH, McEntee MC, Nolan MW, Gieger TL. Evaluation of variables associated with outcomes in 41 dogs with incompletely excised high-grade soft tissue sarcomas treated with definitive-intent radiation therapy with or without chemotherapy. *J Am Vet Med Assoc.* 2020;256: 783-791. doi: 10.2460/javma.256.7.783
36. Del Alcazar CM, Mahoney JA, Dittrich K, Stefanovski D, Church ME. Outcome, prognostic factors and histological characterization of canine gastrointestinal sarcomas. *Vet Comp Oncol.* 2021;19: 578-586. doi: 10.1111/vco.12696
37. Dettwiler M, Mauldin EA, Jastrebski S, Gillette D, Stefanovski D, Durham AC. Prognostic clinical and histopathological features of canine cutaneous epitheliotropic T-cell lymphoma. *Vet Pathol.* 2022: 3009858221140818. doi: 10.1177/03009858221140818
38. Dobson JM, Blackwood LB, McInnes EF, et al. Prognostic variables in canine multicentric lymphosarcoma. *J Small Anim Pract.* 2001;42: 377-384. doi: 10.1111/j.1748-5827.2001.tb02485.x
39. Dolka I, Czopowicz M, Gruk-Jurka A, Wojtkowska A, Sapieryński R, Jurka P. Diagnostic efficacy of smear cytology and Robinson's cytological grading of canine mammary tumors with respect to histopathology, cytomorphometry, metastases and overall survival. *PloS one.* 2018;13: e0191595. doi: 10.1371/journal.pone.0191595
40. Dolka I, Król M, Sapieryński R. Evaluation of apoptosis-associated protein (Bcl-2, Bax, cleaved caspase-3 and p53) expression in canine mammary tumors: An immunohistochemical and prognostic study. *Res Vet Sci.* 2016;105: 124-133. doi: 10.1016/j.rvsc.2016.02.004
41. Donnelly L, Mullin C, Balko J, et al. Evaluation of histological grade and histologically tumour-free margins as predictors of local recurrence in completely excised canine mast cell tumours. *Vet Comp Oncol.* 2015;13: 70-76. doi: 10.1111/vco.12021
42. Donovan TA, Moore FM, Bertram CA, et al. Mitotic Figures-Normal, Atypical, and Imposters: A Guide to Identification. *Vet Pathol.* 2021;58: 243-257. doi: 10.1177/0300985820980049
43. Dunn JK, Bostock DE, Herrtage ME, Jackson KF, Walker MJ. Insulin-secreting tumours of the canine pancreas: Clinical and pathological features of 11 cases. *Journal of Small Animal Practice.* 1993;34: 325-331. doi: 10.1111/j.1748-5827.1993.tb02704.x
44. Dutra AP, Azevedo Júnior GM, Schmitt FC, Cassali GD. Assessment of cell proliferation and prognostic factors in canine mammary gland tumors. *Arquivo Brasileiro de Medicina Veterinária e Zootecnia.* 2008;60: 1403-1412.
45. Edmondson EF, Hess AM, Powers BE. Prognostic significance of histologic features in canine renal cell carcinomas: 70 nephrectomies. *Vet Pathol.* 2015;52: 260-268. doi: 10.1177/0300985814533803
46. Elliott JW, Cripps P, Blackwood L, Berlato D, Murphy S, Grant IA. Canine oral mucosal mast cell tumours. *Vet Comp Oncol.* 2016;14: 101-111. doi: 10.1111/vco.12071
47. Elston LB, Sueiro FA, Cavalcanti JN, Metze K. The importance of the mitotic index as a prognostic factor for survival of canine cutaneous mast cell tumors: a

- validation study. *Vet Pathol.* 2009;46: 362-364, author reply 364-365. doi: 10.1354/vp.46-2-362
48. Ettinger SN, Scase TJ, Oberthaler KT, et al. Association of argyrophilic nucleolar organizing regions, Ki-67, and proliferating cell nuclear antigen scores with histologic grade and survival in dogs with soft tissue sarcomas: 60 Cases (1996-2002). *Journal of the American Veterinary Medical Association.* 2006;228: 1053-1062. doi: 10.2460/javma.228.7.1053
49. Evenhuis JV, Oates A, Hoyer N, Vilander AC, Thamm DH, Worley DR. A retrospective study of canine oral extramedullary plasmacytoma over a 15-year period (July 2004-July 2019): Treatment, histologic parameters and clinical outcomes. *Vet Comp Oncol.* 2023;21: 302-314. 10.1111/vco.12888
50. Flood-Knapik KE, Durham AC, Gregor TP, Sánchez MD, Durney ME, Sorenmo KU. Clinical, histopathological and immunohistochemical characterization of canine indolent lymphoma. *Vet Comp Oncol.* 2013;11: 272-286. doi: 10.1111/j.1476-5829.2011.00317.x
51. Gill V, Leibman N, Monette S, Craft DM, Bergman PJ. Prognostic Indicators and Clinical Outcome in Dogs with Subcutaneous Mast Cell Tumors Treated with Surgery Alone: 43 Cases. *J Am Anim Hosp Assoc.* 2020;56: 215-225. doi: 10.5326/JAAHA-MS-6960
52. Gillespie V, Baer K, Farrelly J, Craft D, Luong R. Canine gastrointestinal stromal tumors: immunohistochemical expression of CD34 and examination of prognostic indicators including proliferation markers Ki67 and AgNOR. *Vet Pathol.* 2011;48: 283-291. doi: 10.1177/0300985810380397
53. Giuliano EA, Chappell R, Fischer B, Dubielzig RR. A matched observational study of canine survival with primary intraocular melanocytic neoplasia. *Veterinary Ophthalmology.* 1999;2: 185-190. doi: 10.1046/j.1463-5224.1999.00080.x
54. Graves GM, Bjorling DE, Mahaffey E. Canine hemangiopericytoma: 23 cases (1967-1984). *J Am Vet Med Assoc.* 1988;192: 99-102.
55. Gregório H, Raposo T, Queiroga FL, Pires I, Pena L, Prada J. High COX-2 expression in canine mast cell tumours is associated with proliferation, angiogenesis and decreased overall survival. *Veterinary and comparative oncology.* 2017;15: 1382-1392. doi: 10.1111/vco.12280
56. Guim TN, Bianchi MV, De Lorenzo C, et al. Relationship Between Clinicopathological Features and Prognosis in Appendicular Osteosarcoma in Dogs. *Journal of Comparative Pathology.* 2020;180: 91-99. doi: 10.1016/j.jcpa.2020.09.003
57. Hahn KA, DeNicola DB, Richardson RC, Hahn EA. Canine oral malignant melanoma: Prognostic utility of an alternative staging system. *Journal of Small Animal Practice.* 1994;35: 251-256.
58. Hammer A, Getzy D, Ogilvie G, Upton M, Klausner J, Kisseberth WC. Salivary gland neoplasia in the dog and cat: survival times and prognostic factors. *J Am Anim Hosp Assoc.* 2001;37: 478-482. doi: 10.5326/15473317-37-5-478
59. Heller DA, Stebbins ME, Reynolds TL, Hauck ML. A retrospective study of 87 cases of canine soft tissue sarcomas. *Int J Appl Res Vet Med.* 2005;3: 81-87.
60. Horta RS, Lavallo GE, Monteiro LN, Souza MCC, Cassali GD, Araújo RB. Assessment of Canine Mast Cell Tumor Mortality Risk Based on Clinical, Histologic, Immunohistochemical, and Molecular Features. *Vet Pathol.* 2018;55: 212-223. doi: 10.1177/0300985817747325
61. Hughes KL, Ehrhart EJ, Rout ED, et al. Diffuse Small B-Cell Lymphoma: A High-Grade Malignancy. *Vet Pathol.* 2021;58: 912-922. doi: 10.1177/0300985820985221
62. Hume CT, Kiupel M, Rigatti L, Shofer FS, Skorupski KA, Sorenmo KU. Outcomes of dogs with grade 3 mast cell tumors: 43 cases (1997-2007). *Journal of the*

- American Animal Hospital Association*. 2011;47: 37-44. doi: 10.5326/JAAHA-MS-5557
63. Iwaki Y, Lindley S, Smith A, Curran KM, Looper J. Canine myxosarcomas, a retrospective analysis of 32 dogs (2003-2018). *BMC Veterinary Research*. 2019;15. doi: 10.1186/s12917-019-1956-z
64. Jeon MD, Leeper HJ, Cook MR, et al. Multi-institutional retrospective study of canine foot pad malignant melanomas: 20 cases. *Vet Comp Oncol*. 2022;20: 854-861. 10.1111/vco.12846
65. Kim D, Pantanowitz L, Schüffler P, et al. (Re) Defining the High-Power Field for Digital Pathology. *J Pathol Inform*. 2020;11: 33. 10.4103/jpi.jpi_48_20
66. Kim SE, Liptak JM, Gall TT, Monteith GJ, Woods JP. Epirubicin in the adjuvant treatment of splenic hemangiosarcoma in dogs: 59 cases (1997-2004). *J Am Vet Med Assoc*. 2007;231: 1550-1557. doi: 10.2460/javma.231.10.1550
67. Kirpensteijn J, Kik M, Rutteman GR, Teske E. Prognostic significance of a new histologic grading system for canine osteosarcoma. *Vet Pathol*. 2002;39: 240-246. doi: 10.1354/vp.39-2-240
68. Kiupel M, Teske E, Bostock D. Prognostic factors for treated canine malignant lymphoma. *Vet Pathol*. 1999;36: 292-300.
69. Knight BJ, Wood GA, Foster RA, Coomber BL. Beclin-1 is a novel predictive biomarker for canine cutaneous and subcutaneous mast cell tumors. *Vet Pathol*. 2022;59: 46-56. doi: 10.1177/03009858211042578
70. Krick EL, Kiupel M, Durham AC, Thaiwong T, Brown DC, Sorenmo KU. Investigating associations between proliferation indices, c-kit, and lymph node stage in canine mast cell tumors. *Journal of the American Animal Hospital Association*. 2017;53: 258-264. doi: 10.5326/JAAHA-MS-6265
71. Kuntz CA, Dernell WS, Powers BE, Devitt C, Straw RC, Withrow SJ. Prognostic factors for surgical treatment of soft-tissue sarcomas in dogs: 75 cases (1986-1996). *J Am Vet Med Assoc*. 1997;211: 1147-1151.
72. Laprie C, Abadie J, Amardeilh MF, Net JL, Lagadic M, Delverdier M. MIB-1 immunoreactivity correlates with biologic behaviour in canine cutaneous melanoma. *Vet Dermatol*. 2001;12: 139-147. doi: 10.1046/j.1365-3164.2001.00236.x
73. Lapsley JM, Wavreille V, Barry S, et al. Risk factors and outcome in dogs with recurrent massive hepatocellular carcinoma: A Veterinary Society of Surgical Oncology case-control study. *Vet Comp Oncol*. 2022;20: 697-709. 10.1111/vco.12824
74. Larsen E, Watson AM, Muñoz Gutiérrez JF. Intranasal mast cell tumors: Clinical, immunohistochemical, and molecular features in 20 dogs. *Vet Pathol*. 2022;59: 915-921. 10.1177/03009858221109100
75. Lascelles BD, Parry AT, Stidworthy MF, Dobson JM, White RA. Squamous cell carcinoma of the nasal planum in 17 dogs. *Vet Rec*. 2000;147: 473-476. doi: 10.1136/vr.147.17.473
76. Laver T, Feldhaeusser BR, Robot CS, et al. Post-surgical outcome and prognostic factors in canine malignant melanomas of the haired skin: 87 cases (2003-2015). *Canadian Veterinary Journal*. 2018;59: 981-987.
77. Linden D, Liptak JM, Vinayak A, et al. Outcomes and prognostic variables associated with primary abdominal visceral soft tissue sarcomas in dogs: A Veterinary Society of Surgical Oncology retrospective study. *Veterinary and comparative oncology*. 2019;17: 265-270. doi: 10.1111/vco.12456
78. Liu JL, Chang KC, Lo CC, Chu PY, Liu CH. Expression of autophagy-related protein Beclin-1 in malignant canine mammary tumors. *BMC Vet Res*. 2013;9: 75. doi: 10.1186/1746-6148-9-75

79. Loukopoulos P, Robinson WF. Clinicopathological relevance of tumour grading in canine osteosarcoma. *J Comp Pathol.* 2007;136: 65-73. doi: 10.1016/j.jcpa.2006.11.005
80. Maas CP, ter Haar G, van der Gaag I, Kirpensteijn J. Reclassification of small intestinal and cecal smooth muscle tumors in 72 dogs: clinical, histologic, and immunohistochemical evaluation. *Vet Surg.* 2007;36: 302-313. doi: 10.1111/j.1532-950X.2007.00271.x
81. Mainenti M, Rasotto R, Carnier P, Zappulli V. Oestrogen and progesterone receptor expression in subtypes of canine mammary tumours in intact and ovariectomised dogs. *Vet J.* 2014;202: 62-68. doi: 10.1016/j.tvjl.2014.06.003
82. Marconato L, Stefanello D, Solari Basano F, et al. Subcutaneous mast cell tumours: A prospective multi-institutional clinicopathological and prognostic study of 43 dogs. *Vet Rec.* 2023: e2991. 10.1002/vetr.2991
83. Martínez CM, Peñafiel-Verdú C, Vilafranca M, et al. Cyclooxygenase-2 expression is related with localization, proliferation, and overall survival in canine melanocytic neoplasms. *Vet Pathol.* 2011;48: 1204-1211. doi: 10.1177/0300985810396517
84. McNiel EA, Ogilvie GK, Powers BE, Hutchison JM, Salman MD, Withrow SJ. Evaluation of prognostic factors for dogs with primary lung tumors: 67 cases (1985-1992). *J Am Vet Med Assoc.* 1997;211: 1422-1427.
85. McNiel EA, Prink AL, O'Brien TD. Evaluation of risk and clinical outcome of mast cell tumours in pug dogs. *Vet Comp Oncol.* 2006;4: 2-8. doi: 10.1111/j.1476-5810.2006.00085.x
86. McPhetridge JB, Scharf VF, Regier PJ, et al. Distribution of histopathologic types of primary pulmonary neoplasia in dogs and outcome of affected dogs: 340 cases (2010-2019). *J Am Vet Med Assoc.* 2021;260: 234-243. doi: 10.2460/javma.20.12.0698
87. McSporran KD. Histologic grade predicts recurrence for marginally excised canine subcutaneous soft tissue sarcomas. *Vet Pathol.* 2009;46: 928-933. doi: 10.1354/vp.08-VP-0277-M-FL
88. Mendez SE, Sykes Crumplar SE, Durham AC. Primary Hemangiosarcoma of the Falciform Fat in Seven Dogs (2007-2015). *J Am Anim Hosp Assoc.* 2020;56: 120-126. doi: 10.5326/jaaha-ms-6967
89. Merickel JL, Pluhar GE, Rendahl A, O'Sullivan MG. Prognostic histopathologic features of canine glial tumors. *Vet Pathol.* 2021;58: 945-951. doi: 10.1177/03009858211025795
90. Meuten D, Munday JS, Hauck M. Time to Standardize? Time to Validate? *Vet Pathol.* 2018;55: 195-199. 10.1177/0300985817753869
91. Meuten DJ, Moore FM, Donovan TA, et al. International Guidelines for Veterinary Tumor Pathology: A Call to Action. *Vet Pathol.* 2021;58: 766-794. 10.1177/03009858211013712
92. Meuten DJ, Moore FM, George JW. Mitotic Count and the Field of View Area: Time to Standardize. *Vet Pathol.* 2016;53: 7-9. 10.1177/0300985815593349
93. Millanta F, Fratini F, Corazza M, Castagnaro M, Zappulli V, Poli A. Proliferation activity in oral and cutaneous canine melanocytic tumours: correlation with histological parameters, location, and clinical behaviour. *Res Vet Sci.* 2002;73: 45-51. doi: 10.1016/s0034-5288(02)00041-3
94. Misdorp W, Hart AA. Prognostic factors in canine mammary cancer. *J Natl Cancer Inst.* 1976;56: 779-786. doi: 10.1093/jnci/56.4.779
95. Misdorp W, Hart AA. Some prognostic and epidemiologic factors in canine osteosarcoma. *J Natl Cancer Inst.* 1979;62: 537-545. doi: 10.1093/jnci/62.3.537

96. Moore AS, Dernell WS, Ogilvie GK, et al. Doxorubicin and BAY 12-9566 for the treatment of osteosarcoma in dogs: a randomized, double-blind, placebo-controlled study. *J Vet Intern Med.* 2007;21: 783-790. doi: 10.1892/0891-6640(2007)21[783:dabftt]2.0.co;2
97. Moore AS, Frimberger AE, Sullivan N, Moore PF. Histologic and immunohistochemical review of splenic fibrohistiocytic nodules in dogs. *J Vet Intern Med.* 2012;26: 1164-1168. doi: 10.1111/j.1939-1676.2012.00986.x
98. Moore AS, Frimberger AE, Taylor D, Sullivan N. Retrospective outcome evaluation for dogs with surgically excised, solitary Kiupel high-grade, cutaneous mast cell tumours. *Vet Comp Oncol.* 2020;18: 402-408. doi: 10.1111/vco.12565
99. Moore AS, Rassnick KM, Frimberger AE. Evaluation of clinical and histologic factors associated with survival time in dogs with stage II splenic hemangiosarcoma treated by splenectomy and adjuvant chemotherapy: 30 cases (2011-2014). *J Am Vet Med Assoc.* 2017;251: 559-565. doi: 10.2460/javma.251.5.559
100. Morello EM, Cino M, Giacobino D, et al. Prognostic value of ki67 and other clinical and histopathological factors in canine apocrine gland anal sac adenocarcinoma. *Animals.* 2021;11. doi: 10.3390/ani11061649
101. Nakagaki KYR, Nunes MM, Garcia APV, De Brot M, Cassali GD. Neuroendocrine Carcinomas of the Canine Mammary Gland: Histopathological and Immunohistochemical Characteristics. *Front Vet Sci.* 2020;7: 621714. doi: 10.3389/fvets.2020.621714
102. Newman SJ, Mrkonjich L, Walker KK, Rohrbach BW. Canine subcutaneous mast cell tumour: diagnosis and prognosis. *J Comp Pathol.* 2007;136: 231-239. doi: 10.1016/j.jcpa.2007.02.003
103. Nóbrega DF, Sehaber VF, Madureira R, Bracarense APFRL. Canine Cutaneous Haemangiosarcoma: Biomarkers and Survival. *Journal of Comparative Pathology.* 2019;166: 87-96. doi: 10.1016/j.jcpa.2018.10.181
104. O'Connell K, Thomson M. Evaluation of prognostic indicators in dogs with multiple, simultaneously occurring cutaneous mast cell tumours: 63 cases. *Vet Comp Oncol.* 2013;11: 51-62. doi: 10.1111/j.1476-5829.2011.00301.x
105. Ogilvie GK, Powers BE, Mallinckrodt CH, Withrow SJ. Surgery and doxorubicin in dogs with hemangiosarcoma. *J Vet Intern Med.* 1996;10: 379-384. doi: 10.1111/j.1939-1676.1996.tb02085.x
106. Ouzzani M, Hammady H, Fedorowicz Z, Elmagarmid A. Rayyan — a web and mobile app for systematic reviews. *Systematic Reviews.* 2016;5: 210; <https://rayyan.ai/>. doi: 10.1186/s13643-016-0384-4
107. Pazzi P, Kavkovsky A, Shipov A, Segev G, Dvir E. Spirocerca lupi induced oesophageal neoplasia: Predictors of surgical outcome. *Vet Parasitol.* 2018;250: 71-77. doi: 10.1016/j.vetpar.2017.11.013
108. Pecceu E, Serra Varela JC, Handel I, Piccinelli C, Milne E, Lawrence J. Ultrasound is a poor predictor of early or overt liver or spleen metastasis in dogs with high-risk mast cell tumours. *Vet Comp Oncol.* 2020;18: 389-401. doi: 10.1111/vco.12563
109. Phillips BS, Kass PH, Naydan DK, Winthrop MD, Griffey SM, Madewell BR. Apoptotic and proliferation indexes in canine lymphoma. *J Vet Diagn Invest.* 2000;12: 111-117. doi: 10.1177/104063870001200202
110. Porcellato I, Brachelente C, Cappelli K, et al. FoxP3, CTLA-4, and IDO in Canine Melanocytic Tumors. *Vet Pathol.* 2021;58: 42-52. doi: 10.1177/0300985820960131
111. Pradel J, Berlato D, Dobromylskyj M, Rasotto R. Prognostic significance of histopathology in canine anal sac gland adenocarcinomas: Preliminary results in a

- retrospective study of 39 cases. *Vet Comp Oncol.* 2018;16: 518-528. doi: 10.1111/vco.12410
112. Preziosi R, Sarli G, Paltrinieri M. Prognostic value of intratumoral vessel density in cutaneous mast cell tumors of the dog. *J Comp Pathol.* 2004;130: 143-151. doi: 10.1016/j.jcpa.2003.10.003
113. Prouteau A, Chocteau F, de Brito C, et al. Prognostic value of somatic focal amplifications on chromosome 30 in canine oral melanoma. *Vet Comp Oncol.* 2020;18: 214-223. doi: 10.1111/vco.12536
114. Ramos-Vara JA, Beissenherz ME, Miller MA, et al. Retrospective study of 338 canine oral melanomas with clinical, histologic, and immunohistochemical review of 129 cases. *Vet Pathol.* 2000;37: 597-608. doi: 10.1354/vp.37-6-597
115. Ressel L, Puleio R, Loria GR, et al. HER-2 expression in canine morphologically normal, hyperplastic and neoplastic mammary tissues and its correlation with the clinical outcome. *Res Vet Sci.* 2013;94: 299-305. doi: 10.1016/j.rvsc.2012.09.016
116. Rigas K, Biasoli D, Polton G, et al. Mast cell tumours in dogs less than 12 months of age: a multi-institutional retrospective study. *J Small Anim Pract.* 2020;61: 449-457. doi: 10.1111/jsap.13181
117. Robinson WP, Elliott J, Baines SJ, Owen L, Shales CJ. Intramuscular mast cell tumors in 7 dogs. *Can Vet J.* 2017;58: 931-935.
118. Romansik EM, Reilly CM, Kass PH, Moore PF, London CA. Mitotic index is predictive for survival for canine cutaneous mast cell tumors. *Vet Pathol.* 2007;44: 335-341. doi: 10.1354/vp.44-3-335
119. Saam DE, Liptak JM, Stalker MJ, Chun R. Predictors of outcome in dogs treated with adjuvant carboplatin for appendicular osteosarcoma: 65 cases (1996-2006). *J Am Vet Med Assoc.* 2011;238: 195-206. doi: 10.2460/javma.238.2.195
120. Sabattini S, Rigillo A, Foiani G, et al. Clinicopathologic features and biologic behavior of canine splenic nodules with stromal, histiocytic and lymphoid components. *Front Vet Sci.* 2022;9: 962685. doi: 10.3389/fvets.2022.962685
121. Sánchez J, Ramirez GA, Buendia AJ, et al. Immunohistochemical characterization and evaluation of prognostic factors in canine oral melanomas with osteocartilaginous differentiation. *Vet Pathol.* 2007;44: 676-682. doi: 10.1354/vp.44-5-676
122. Santos AA, Lopes CC, Ribeiro JR, et al. Identification of prognostic factors in canine mammary malignant tumours: a multivariable survival study. *BMC Vet Res.* 2013;9: 1. doi: 10.1186/1746-6148-9-1
123. Santos M, Correia-Gomes C, Marcos R, et al. Value of the Nottingham Histological Grading Parameters and Nottingham Prognostic Index in Canine Mammary Carcinoma. *Anticancer Res.* 2015;35: 4219-4227.
124. Sarli G, Preziosi R, Benazzi C, Castellani G, Marcato PS. Prognostic value of histologic stage and proliferative activity in canine malignant mammary tumors. *J Vet Diagn Invest.* 2002;14: 25-34. doi: 10.1177/104063870201400106
125. Schlag AN, Johnson T, Vinayak A, Kuvaldina A, Skinner OT, Wustefeld-Janssens BG. Comparison of methods to determine primary tumour size in canine apocrine gland anal sac adenocarcinoma. *J Small Anim Pract.* 2020;61: 185-189. doi: 10.1111/jsap.13104
126. Schott CR, Tatiarsky LJ, Foster RA, Wood GA. Histologic Grade Does Not Predict Outcome in Dogs with Appendicular Osteosarcoma Receiving the Standard of Care. *Vet Pathol.* 2018;55: 202-211. doi: 10.1177/0300985817747329
127. Schultheiss PC. Histologic features and clinical outcomes of melanomas of lip, haired skin, and nail bed locations of dogs. *J Vet Diagn Invest.* 2006;18: 422-425. doi: 10.1177/104063870601800422

128. Schultheiss PC. A retrospective study of visceral and nonvisceral hemangiosarcoma and hemangiomas in domestic animals. *J Vet Diagn Invest.* 2004;16: 522-526. doi: 10.1177/104063870401600606
129. Schwab TM, Popovitch C, DeBiasio J, Goldschmidt M. Clinical outcome for MCTs of canine pinnae treated with surgical excision (2004-2008). *J Am Anim Hosp Assoc.* 2014;50: 187-191. doi: 10.5326/JAAHA-MS-6039
130. Selting KA, Powers BE, Thompson LJ, et al. Outcome of dogs with high-grade soft tissue sarcomas treated with and without adjuvant doxorubicin chemotherapy: 39 cases (1996-2004). *J Am Vet Med Assoc.* 2005;227: 1442-1448. doi: 10.2460/javma.2005.227.1442
131. Shiu KB, Flory AB, Anderson CL, et al. Predictors of outcome in dogs with subcutaneous or intramuscular hemangiosarcoma. *J Am Vet Med Assoc.* 2011;238: 472-479. doi: 10.2460/javma.238.4.472
132. Sierra Matiz OR, Santilli J, Anai LA, et al. Prognostic significance of Ki67 and its correlation with mitotic index in dogs with diffuse large B-cell lymphoma treated with 19-week CHOP-based protocol. *J Vet Diagn Invest.* 2018;30: 263-267. doi: 10.1177/1040638717743280
133. Silvestri S, Porcellato I, Mechelli L, Menchetti L, Rapastella S, Brachelente C. Tumor Thickness and Modified Clark Level in Canine Cutaneous Melanocytic Tumors. *Vet Pathol.* 2019;56: 180-188. doi: 10.1177/0300985818798094
134. Simoes JP, Schoning P, Butine M. Prognosis of canine mast cell tumors: a comparison of three methods. *Vet Pathol.* 1994;31: 637-647. doi: 10.1177/030098589403100602
135. Simon D, Ruslander DM, Rassnick KM, et al. Orthovoltage radiation and weekly low dose of doxorubicin for the treatment of incompletely excised soft-tissue sarcomas in 39 dogs. *Vet Rec.* 2007;160: 321-326. doi: 10.1136/vr.160.10.321
136. Skor O, Fuchs-Baumgartinger A, Tichy A, Kleiter M, Schwendenwein I. Pretreatment leukocyte ratios and concentrations as predictors of outcome in dogs with cutaneous mast cell tumours. *Vet Comp Oncol.* 2017;15: 1333-1345. doi: 10.1111/vco.12274
137. Skorupski KA, Alarcón CN, de Lorimier LP, LaDouceur EEB, Rodriguez CO, Rebhun RB. Outcome and clinical, pathological, and immunohistochemical factors associated with prognosis for dogs with early-stage anal sac adenocarcinoma treated with surgery alone: 34 cases (2002-2013). *J Am Vet Med Assoc.* 2018;253: 84-91. doi: 10.2460/javma.253.1.84
138. Sledge DG, Webster J, Kiupel M. Canine cutaneous mast cell tumors: A combined clinical and pathologic approach to diagnosis, prognosis, and treatment selection. *Vet J.* 2016;215: 43-54. doi: 10.1016/j.tvjl.2016.06.003
139. Spangler WL, Culbertson MR, Kass PH. Primary mesenchymal (nonangiomatous/nonlymphomatous) neoplasms occurring in the canine spleen: anatomic classification, immunohistochemistry, and mitotic activity correlated with patient survival. *Vet Pathol.* 1994;31: 37-47. doi: 10.1177/030098589403100105
140. Spangler WL, Kass PH. The histologic and epidemiologic bases for prognostic considerations in canine melanocytic neoplasia. *Vet Pathol.* 2006;43: 136-149. doi: 10.1354/vp.43-2-136
141. Spangler WL, Kass PH. Pathologic and prognostic characteristics of splenomegaly in dogs due to fibrohistiocytic nodules: 98 cases. *Vet Pathol.* 1998;35: 488-498. doi: 10.1177/030098589803500603
142. Stefanello D, Avallone G, Ferrari R, Roccabianca P, Boracchi P. Canine cutaneous perivascular wall tumors at first presentation: clinical behavior and

- prognostic factors in 55 cases. *J Vet Intern Med.* 2011;25: 1398-1405. doi: 10.1111/j.1939-1676.2011.00822.x
143. Tanis JB, Simlett-Moss AB, Ossowksa M, et al. Canine anal sac gland carcinoma with regional lymph node metastases treated with saccullectomy and lymphadenectomy: Outcome and possible prognostic factors. *Vet Comp Oncol.* 2022;20: 276-292. doi: 10.1111/vco.12774
144. Thamm DH, Weishaar KM, Charles JB, Ehrhart EJ, 3rd. Phosphorylated KIT as a predictor of outcome in canine mast cell tumours treated with toceranib phosphate or vinblastine. *Vet Comp Oncol.* 2020;18: 169-175. doi: 10.1111/vco.12525
145. Thompson JJ, Morrison JA, Pearl DL, et al. Receptor Tyrosine Kinase Expression Profiles in Canine Cutaneous and Subcutaneous Mast Cell Tumors. *Vet Pathol.* 2016;53: 545-558. doi: 10.1177/0300985815610388
146. Thompson JJ, Pearl DL, Yager JA, Best SJ, Coomber BL, Foster RA. Canine subcutaneous mast cell tumor: characterization and prognostic indices. *Vet Pathol.* 2011;48: 156-168. doi: 10.1177/0300985810387446
147. Thompson JJ, Yager JA, Best SJ, et al. Canine subcutaneous mast cell tumors: cellular proliferation and KIT expression as prognostic indices. *Vet Pathol.* 2011;48: 169-181. doi: 10.1177/0300985810390716
148. Treggiari E, Valenti P, Porcellato I, Maresca G, Romanelli G. Retrospective analysis of outcome and prognostic factors of subcutaneous mast cell tumours in dogs undergoing surgery with or without adjuvant treatment. *Vet Comp Oncol.* 2023. doi: 10.1111/vco.12902
149. Vail DM, Powers BE, Getzy DM, et al. Evaluation of prognostic factors for dogs with synovial sarcoma: 36 cases (1986-1991). *J Am Vet Med Assoc.* 1994;205: 1300-1307.
150. Valli VE, Kass PH, San Myint M, Scott F. Canine lymphomas: association of classification type, disease stage, tumor subtype, mitotic rate, and treatment with survival. *Vet Pathol.* 2013;50: 738-748. doi: 10.1177/0300985813478210
151. van Lelyveld S, Warland J, Miller R, et al. Comparison between Ki-67 index and mitotic index for predicting outcome in canine mast cell tumours. *J Small Anim Pract.* 2015;56: 312-319. doi: 10.1111/jsap.12320
152. Vargas THM, Pulz LH, Ferro DG, et al. Galectin-3 Expression Correlates with Post-surgical Survival in Canine Oral Melanomas. *J Comp Pathol.* 2019;173: 49-57. doi: 10.1016/j.jcpa.2019.10.003
153. Vascellari M, Giantin M, Capello K, et al. Expression of Ki67, BCL-2, and COX-2 in canine cutaneous mast cell tumors: association with grading and prognosis. *Vet Pathol.* 2013;50: 110-121. doi: 10.1177/0300985812447829
154. Wei BR, Halsey CH, Hoover SB, et al. Agreement in Histological Assessment of Mitotic Activity Between Microscopy and Digital Whole Slide Images Informs Conversion for Clinical Diagnosis. *Acad Pathol.* 2019;6: 2374289519859841. doi: 10.1177/2374289519859841
155. Wilcock BP, Peiffer RL, Jr. Morphology and behavior of primary ocular melanomas in 91 dogs. *Vet Pathol.* 1986;23: 418-424. doi: 10.1177/030098588602300411
156. Willcox JL, Marks SL, Ueda Y, Skorupski KA. Clinical features and outcome of dermal squamous cell carcinoma in 193 dogs (1987-2017). *Vet Comp Oncol.* 2019;17: 130-138. doi: 10.1111/vco.12461
157. Wittenberns BM, Thamm DH, Palmer EP, Regan DP. Canine Non-Angiogenic, Non-Myogenic Splenic Stromal Sarcoma: a Retrospective Clinicopathological Analysis and Investigation of Podoplanin as a Marker of Tumour Histogenesis. *J Comp Pathol.* 2021;188: 1-12. doi: 10.1016/j.jcpa.2021.07.006

158. Yale AD, Priestnall SL, Pittaway R, Taylor AJ. Thymic epithelial tumours in 51 dogs: Histopathologic and clinicopathologic findings. *Vet Comp Oncol.* 2022;20: 50-58. doi: 10.1111/vco.12705
159. Yamamoto S, Fukushima R, Hirakawa A, Abe M, Kobayashi M, Machida N. Histopathological and immunohistochemical evaluation of malignant potential in canine aortic body tumours. *J Comp Pathol.* 2013;149: 182-191. doi: 10.1016/j.jcpa.2012.12.007
160. Yamazaki H, Sasai H, Tanaka M, et al. Assessment of biomarkers influencing treatment success on small intestinal lymphoma in dogs. *Vet Comp Oncol.* 2021;19: 123-131. doi: 10.1111/vco.12653
161. Zini E, Nolli S, Ferri F, et al. Pheochromocytoma in Dogs Undergoing Adrenalectomy. *Vet Pathol.* 2019;56: 358-368. doi: 10.1177/0300985818819174